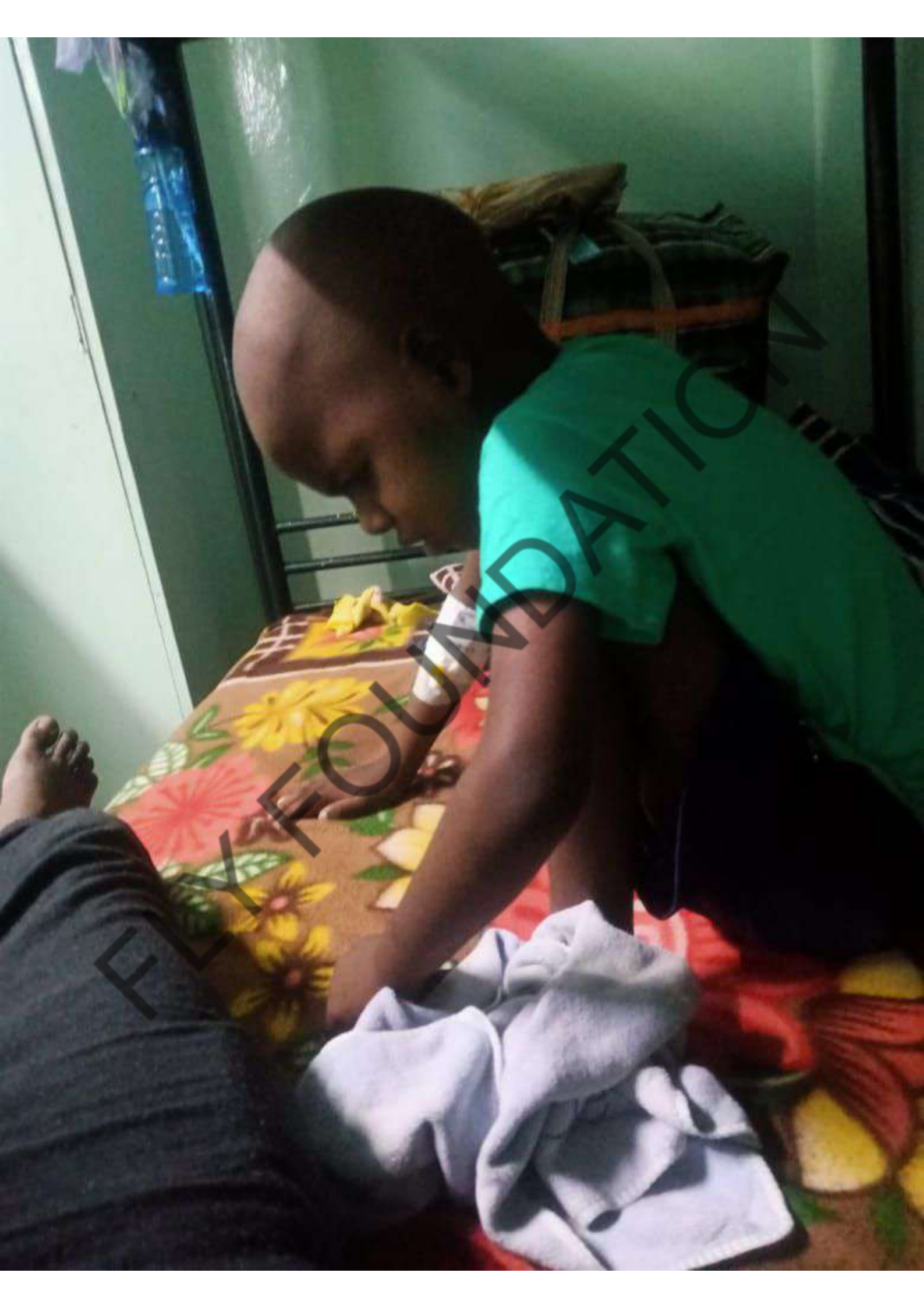
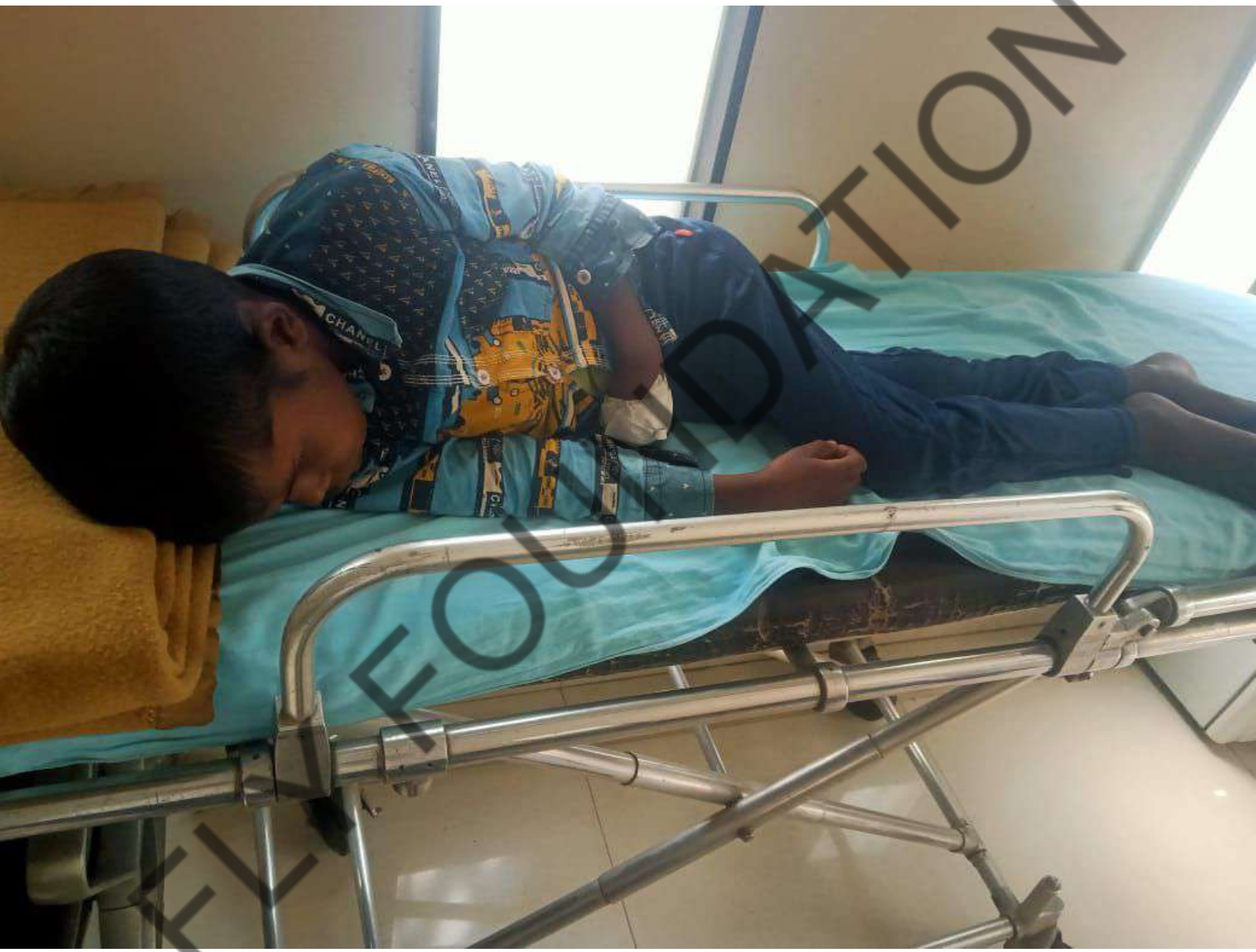






MIS 2023 PATIENT'S NAME: ROHIT NISHAD

REF. BY: DR. AIIMS

TEST NAME: 3T MRI SCAN - CEMRI HEAD & ORBITS

AGE/SEX: 5/M

REG. ID: RND5658

EXAM. DATE: 28-MAR-2023

CEMRI BRAIN AND ORBIT

TECHNIQUE: -MR IMAGING OF THE BRAIN WAS PERFORMED, MR SCANNER USING HEAD COIL. T1 FLAIR, FSE T2, GRE T2*, AXIAL, FSE T2-- SAGITTAL AND T2 FLAIR CORONAL IMAGES WERE ACQUIRED. THE STUDY WAS SUPPLEMENTED WITH DIFFUSION WEIGHTED IMAGES USING EPI SEQUENCE. POST CONTRAST IMAGES IN AXIAL, CORONAL AND SAGITTAL PLANES.

CLINICAL DETAILS: - F/U OPERATED CASE, POST CHEMO.

OBSERVATION: -

Prosthesis of left ocular globe noted.

There is altered signal intensity mass lesion occupying the entire posterior chamber of right orbit. The lesion is isointense on T1 and T2W images. Post contrast images reveal moderate intense heterogeneous enhancement of the lesion. No retro-orbital extension noted. The lesion measures about 20 x 18 x 20mm - likely retinoblastoma.

Right ocular globe, extraocular muscles and optic nerve sheath complexes are otherwise normal.

The cerebral parenchyma shows normal signal characteristics. Myelination pattern of the brain is normal. No evidence of restricted diffusion noted.

The basal ganglia, thalami and internal capsules appear normal.

The mid-brain, pons and medulla appear normal. The cerebellum appears normal.

The ventricular system appears normal. The septum is in mid line. The sulci, fissures & basal cisterns appear normal.

The pituitary gland, optic chiasm and bilateral parasellar regions appear normal.

The corpus callosum appears normal.

Intracranial vascular structures in view are normal.

Bilateral seventh-eighth cranial nerve complexes and inner ear structures are normal. Both angle cisterns are normal.

IMPRESSION: CEMR FINDINGS REVEAL:-

- PROSTHESIS OF LEFT OCULAR GLOBE.
- ALTERED SIGNAL INTENSITY MASS LESION OCCUPYING ENTIRE POSTERIOR CHAMBER OF RIGHT ORBIT WITH MODERATE INTENSE HETEROGENEOUS ENHANCEMENT OF LESION ON POST CONTRAST IMAGES WITH NO RETRO-ORBITAL EXTENSION - LIKELY RETINOBLASTOMA.

Please correlate clinically.

Dr. Sacchidanand Purkait
Consultant Radiologist

Dr. K. K. MISHRA
Consultant Radiologist..

Dr. Bhavesh Patel
Consultant Radiologist

Dr. Ravianka Arora
Consultant Radiologist

Firefox

<https://ehospital.aiims.edu/ehospital/HR/AppointmentPrintAppoint...>



नकदी रसीद / CASH RECEIPT
ALL INDIA INSTITUTE OF MEDICAL SCIENCES
असारी नगर, नई दिल्ली-110029 / Ansari Nagar, New Delhi-110029
(AIIMS)

दूरफोन 25588600
Phones 25588700

New Delhi,

रसीद संख्या / Receipt No.

जमाकर्ता / Received From

के नामे / ON ACCOUNT OF

अखिल भारतीय आयुर्विज्ञान संस्थान, नई दिल्ली

APPOINTMENT SLIP नियुक्ति पर्ची

Follow-up Patient
Advance

दिनांक / Date

रोगी प्रकार / Patient Type :

कल संख्या / No. of Slips

Done By-Mr.MANISH KUMAR 2 DEO SWSC

General ₹ 0.0

Department Name: Paediatrics/Paediatric

Appointment Date: 30/03/2024

Reporting Time: 8:00 AM-9:00 AM

Appointment Request date	26/03/2024		
Name of Patient	MR. ROHIT NISHAD	Appointment No	2024032615764
Sex	Male	Age	6 years 2 months 27 days
Contact Details	Mobile: XXXXXX967	Request Mode	counter

Remarks:

Your UHID Is : 105817243.

Book Online appointment from : <https://ors.gov.in> Developed by NIC

प्रदान का प्रकार / Payment Mode :

पये / INR (Rs.) :

पये शब्दों में / Rs. in Words

यह कम्प्यूटर द्वारा जारी की गई रसीद है और इसमें हस्ताक्षर और मोहर अपेक्षित नहीं है।

THIS IS COMPUTER GENERATED SLIP AND DOES NOT REQUIRE SIGNATURE AND STAMP

2024032615764

Firefox

https://ehospital.aimc.edu.in/original/1/ Appointment/printAppointment



अखिल भारतीय आयुर्विज्ञान संस्थान, नई दिल्ली
ALL INDIA INSTITUTE OF MEDICAL SCIENCES (AIIMS)
असारी नगर, दिल्ली-110029 / Ansar Nagar, New Delhi-110029

फ़ोन : 22588000
फ़ैक्स : 22588002

निश्चित पर्ची

APPOINTMENT SLIP



रसीद संख्या / Receipt No. 2024031611290
जनांकित डॉ. रसना कुमार देव स्वस्ति (Follow-up) General ₹ 0.0
ऑपीडी नंबर / OPD / UHID No. 2024031611290
Department Name: Paediatrics/Paediatric
के नाम / ON ACCOUNT OF Reporting Time: 8:00 AM-9:00 AM

Doctor Name	Dr. RACHNA SETHI	Appointment Request date	16/03/2024
Name of Patient	MR. ROHIT NISHAD	Appointment No.	2024031611290
Sex	Male	Age	6 years 2 months 17 days
Contact Details	Mobile: XXXXXXXX967	Request Mode	counter
Queue No.	F16		

Remarks:

Your UHID is : 105817243.

Book Online appointment from : <https://ors.gov.in> Developed by NIC

भुगतान का प्रकार / Payment Mode :

रुपये / INR/RS.

रुपये शब्दों में / Rupees in words

यह कम्प्यूटर द्वारा जारी की गई रसीद है और इसमें हस्ताक्षर और मोहर अपेक्षित नहीं है।
THIS IS A COMPUTER GENERATED RECEIPT AND DOES NOT REQUIRE SIGNATURE AND STAMP

Firefox

<https://ehospital.aiims.edu/ehospital/HRC/Appointment/printAppoi...>



अखिल भारतीय आयुर्विज्ञान संस्थान, नई दिल्ली
All India Institute of Medical Sciences (AIIMS)
असारी नगर, नई दिल्ली-110029

CASH RECEIPT

INDIA INSTITUTE OF MEDICAL SCIENCES
Ansari Nagar, New Delhi-110029

फोन / 26588500
फोन / 26588700

निवृत्ति पर्ची

रसीद संख्या / Receipt No. APPOINTMENT SLIP

डॉ. राक्षस कुमार देव स्वस्ति (Follow-up) General ₹ 0.0 Patient Type :

जन्म तिथि / Date of Birth : 09/03/2018
Department Name: Paediatrics/Paediatric
के नाम / ON ACCOUNT OF

Appointment Date: 20/03/2024
Reporting Time: 8:00 AM-9:00 AM

Doctor Name	Dr. RACHNA SETH	Appointment Request date	16/03/2024
Name of Patient	MR. ROHIT NISHAD	Appointment No	2024031611290
Sex	Male	Age	6 years 2 months 17 days
Contact Details	Mobile: XXXXXXXX967	Request Made	counter
Queue No.	F16		

Remarks:

Your UHID is : 105817243.

Book Online appointment from : <https://ais.gov.in> Developed by NIC

भुगतान का प्रकार / Payment Mode:

सफ़े / INR

सफ़े शब्दों में / Rs. in Words

यह कम्प्यूटर द्वारा जारी की गई रसीद है और इसमें हस्ताक्षर और मोहर अपेक्षित नहीं है।
THIS IS COMPUTER GENERATED SLIP AND DOES NOT REQUIRE SIGNATURE AND STAMP

method 1641M210

GP 8 (post nucleolar) → after default
GP 0

AC discussion: no intracellular
no intracellular extension

staging w/ → CS → glycoprotein: acellular
BMA and Bx
not awaited

PE 7 C7 dated for
9/5/24

echo -

evening @ word SA today ✓
[or shawan] [4 PM] ✓

points (10/3) 13

11,600
7000 2.6/20

urea 32.5
Creat 0.5

LFT (N)

Syp cause 7 (2m) 135m3

5m 10 705
0-0-0
| x 3d
P10 B0
0-0

→ tab

0 x A
(4m)

(12)

tab

ELY FOUNDATION

15m 1

10

705 x 3d

augmented chemo
week "0"

① inj: VINORELBINE
[check
count
rateng] [24/12/24]

[Lut
[Bsa
Advice

② inj DNS

EMSET inj
DEXA inj

③ inj CYCLOPHOSPHAMIDE
[24/12/24]

④ inj MESNA

⑤

350 mg / 100 ml

1000 mg / 100 ml
NS in 100 ml
NS in 2 hrs

⑥

⑦

[ilulo
local

PKS

PCN

⑧ [Lut
[Bsa
Advice

⑨

⑩ postchemo:

⑪

PKS


PCN

5. Post chemo: ~~of~~ ERSET 4mg 1 tab TDS
of DEXA 4mg 1 tab BD

Inj: G-CSF 800µg S.C OD x 5 d | H11 ANC
recovery

6. N/V on 24/4/2024 T CBC

7. Dieffiam review -


Dr. Tanuja
DM, Pediatric Oncology
AIIMS, New Delhi

SBI - KIOSK BANKING
Identity Card

Card Number: 08281075958

Account Number: 38745999013

IFSC Code: SBIN0002516

First Name: SURAJ

Middle Name: KUNAR

Last Name: NISHAG

Address: SO VERVICK NISHA VILL

AWADI PUR SARDAR

PO SARDAR

TST-GOANPUR

Village Name: BT SARDARNAGAR

Pin Code: 272202



ELY FOUNDATION

Download Date: 10/11/2021



भारत सरकार
Government of India



रोहित निषाद
Rohit Nishad
जन्म तिथि/DOB: 30/12/2017
पुरुष/ MALE

30/12/2021

यह आधार 14 वर्ष की उम्र तक ही वैध है

9794

VID : 9151 8291 9024 2799

मेरा आधार, मेरी पहचान



भारतीय विशिष्ट पहचान प्राधिकरण

Unique Identification Authority of India



पता:

द्वारा: सुरज कुमार निषाद, अवधपुर शांति देवी की छावनी,
अवधा पुर, गोरखपुर,
उत्तर प्रदेश - 273202

Address:

C/O: Suraj Kumar Nishad, awadhpur shanti
devi ki chawani, Awadha Pur, Gorakhpur,
Uttar Pradesh - 273202



9794

1947



help@uidai.gov.in

www

www.uidai.gov.in